

Intra-biliary rupture of hepatic hydatid cyst presenting with obstructive jaundice

RanendraHajong¹, DonkumarKhongwar², MadhurAnand³, NarangNaku³,
K Lenish Singh³, ManashPratim Boruah³

¹Associate professor, ²assistant professor, ³resident doctors.

Department of General surgery, North Eastern Indira Gandhi Regional Institute of Health & Medical Sciences, Shillong

Corresponding author: Donkumar Khongwar, assistant professor, general surgery NEIGRIHMS, Shillong.

Abstract:

Context: Rupture of a hydatid cyst into the biliary tree is the most common complication, occurring in 5-25% of patients of hepatic hydatid cyst. The communication between the biliary tree and the hydatid cyst can be frank or occult. In case of intrabiliary rupture of liver hydatid cysts, the most apparent signs and symptoms are fever, jaundice, and right upper quadrant pain.

Case report: A fifty year old male patient presented with pain in the upper abdomen with yellowish discoloration of eyes. The patient also had fever with chills and rigor. Ultrasonography of the abdomen and magnetic resonance cholangiography showed a cystic lesion with the cyst membranes communicating to the left biliary radicles. Broad spectrum antibiotics and albendazole was given for two weeks followed by surgery. At surgery cyst aspiration, common bile duct exploration, removal of the cyst membranes from the bile ducts and choledochoduodenostomy were done. Postoperatively the patient recovered uneventfully.

Conclusion: Hydatid cyst should be kept as one of the differential diagnoses of obstructive jaundice and can be managed by conventional surgical techniques.

Key words: Hepatic hydatid cyst; intrabiliary rupture; obstructive jaundice; choledochoduodenostomy.

I. Introduction:

Echinococcosis is endemic in many Mediterranean countries, the Middle and Far East, South America, Australia, and east Africa¹. Most patients have a single organ involved and harbor a solitary cyst, localized in approximately two thirds of the patients in the liver. Some cysts may grow (average increase, 1-30 mm/y) and then persist without a noticeable change for many years; others may collapse and can completely disappear². An enlarging cyst may cause compressive atrophy of surrounding hepatocytes and fibrosis. Compression and displacement of biliary ducts are frequent. At the point of contact with a biliary duct, a spontaneous rupture may occur. This communicating intrabiliary rupture has been classified as a frank perforation with overt passage of hydatid material into the biliary tract and as occult leakage with signs of suppuration only³. The most common clinical manifestations of frank intra-biliary rupture are colicky right hypochondrial pain and obstructive jaundice accompanied by fever and chills^{4,5}.

Reporting here is a case of intra-biliary rupture of hepatic hydatid cyst causing obstructive jaundice and managed successfully by choledochoduodenostomy.

II. Case report:

A fifty year old male patient presented with pain in the upper abdomen with yellowish discoloration of eyes since the last two weeks. The patient also had fever with chills and rigor for the last one week. The patient had predominantly conjugated hyperbilirubinemia and the total serum bilirubin was 12 milligram/decilitre. Ultrasonography of the abdomen showed a large cystic lesion originating mainly from the left lobe of liver. Magnetic resonance cholangiography showed a cystic lesion with the cyst membranes communicating to the left biliary radicles and extending to the common bile duct causing distension of gallbladder. T2 axial images reveal the hydatid cyst communicating with the left main hepatic duct. There is significant dilatation of bilateral hepatic ducts - left more than right side (Figure 1).

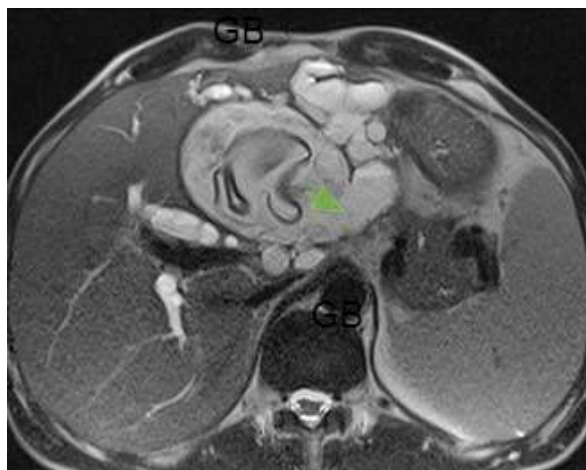


Figure 1 showing T2 axial images reveal the hydatid cyst communicating with the left main hepatic duct (green arrow).

3D Space and T2 axial sequences in coronal plane shows the membrane from the hydatid cyst prolapsing into the extra hepatic biliary tree including the CHD (common hepatic duct) and CBD (common bile duct) causing significant dilatation of the proximal biliary tree. There is significant dilatation of the GB (gallbladder) suggesting obstruction distal to the cystohepatic junction(Figure2).

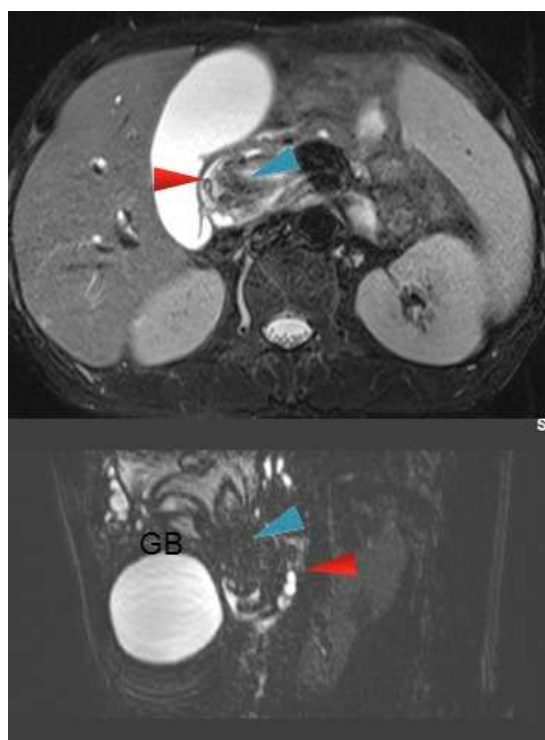


Figure 2 showing 3D Space and T2 axial images of hydatid membrane prolapsing into the extra hepatic biliary tree (Red arrow- CBD wall, blue arrow- hydatidmembranes).

Broad spectrum antibiotics and albendazole was given for two weeks followed by surgery. At surgery marsupialization of the cyst, followed by common bile duct exploration, removal of the remaining cyst membranes from the bile ducts and choledochoduodenostomy were done. Postoperatively the patient recovered uneventfully and was doing fine till one year of follow-up.

III. Discussion:

The rupture may be classified as: contained rupture when the endocyst is torn, but the cyst content is confined within the pericyst; communicating rupture consists of tear of the endocyst with loss of the cyst content via small biliary ducts and direct rupture when a tear of both endocyst and pericyst occurs, allowing the cyst

content to spill into the peritoneal or pleural spaces⁶. Potential sites of rupture are peritoneum, bile ducts, pleural space, thorax, and visceral organs such as stomach or duodenum⁶.

A frank intrabiliary rupture of a cyst may lead to obstruction of the biliary system, cholangitis, and septicemia, with a 50% mortality rate⁷. It has also been suggested that biliary cirrhosis could be a late sequel⁸. Moreover, acute pancreatitis and acute cholecystitis caused by hydatid material were described in the literature^{9,10}. Hence early diagnosis and treatment of an intrabiliary rupture of a liver hydatid cyst are warranted.

Ultrasonography or computed tomography may suggest the diagnosis of a frank intrabiliary rupture in most of the cases¹¹⁻¹³. ERCP (Endoscopic retrograde cholangiopancreatography) is the reference standard in the diagnosis of many biliary tract abnormalities and probably is the most reliable preoperative imaging method for visualization of biliary rupture¹⁴. MRCP (Magnetic resonance cholangiopancreatography) shows a characteristic intense rim, daughter cysts, detachment of the membranes, and dilated biliary tree containing hydatid material^{15,16}.

The classic treatment for hydatid cysts ruptured into the bile ducts is surgery with exploration of the common bile duct through a choledochotomy, clearance of cyst remnants, placement of a T tube, choledochoduodenostomy, surgical excision of the hydatid cyst by enucleation or pericystectomy and partial hepatectomy¹⁵.

The aim is to remove the entire disease while minimizing complications. Conservative procedures are safe and technically simple, and are useful in the management of uncomplicated hydatid cysts¹⁷.

IV. Conclusion:

The case is being reported here to emphasise the fact that hydatid cyst should be kept as one of the differential diagnoses in patients with obstructive jaundice. The cyst may appear menacing but most of the cases can be managed by simple surgical procedures with minimal morbidity.

Conflicts of interest: None to disclose.

References:

- [1]. Milicevic M. Hydatid cyst. Blumgart LHed.Surgery of Liver and Biliary Tract. Edinburgh, Scotland Churchill Livingstone Inc1994;1121- 1150.
- [2]. WHO Informal Working Group on Echinococcosis, Guidelines for treatment of cystic and alveolar echinococcosis in humans. Bull World Health Organ. 1996;74: 231- 242.
- [3]. Hankins JR. Management of complicated hepatic hydatid cysts. Ann Surg 1963;158: 1020- 1034.
- [4]. Dadoukis J, Gamvros O, Aletras H. Intrabiliary rupture of the hydatid cyst of the liver. World J Surg 1984; 8:786-790.
- [5]. Alper A, Ariogul O, Emre A, et al. Choledochoduodenostomy for intrabiliary rupture of hydatid cysts of liver. Br J Surg 1987; 74:243-245.
- [6]. Spârchez Z, Osian G, Onica A, et al. Ruptured hydatid cyst of the liver with biliary obstruction: presentation of a case and review of the literature. Rom J Gastroenterol 2004; 13:245-250.
- [7]. Lewall DB, McCorkellSJ. Rupture of echinococcal cysts: diagnosis, classification, and clinical implications. Am J Roentgenol 1986;146: 391- 394.
- [8]. Kattan YB. Intrabiliary rupture of hydatid cyst of the liver. Ann R CollSurgEngl 1977;59: 108- 114.
- [9]. Saez-Royuela F, Yuguero L, Lopez-Morante A, et al. Acute pancreatitis caused by hydatid membranes in the biliary tract: treatment with endoscopic sphincterotomy. GastrointestEndosc 1999;49: 793- 796.
- [10]. Khalil SA, Smith BM, Mac Lean JD, et al. Acute cholecystitis and cholangitis caused by echinococcosis granulosis. Am J Gastroenterol 1996;91: 805- 807.
- [11]. Zargar SA, Khuroo MS, Khan BA, et al. Intrabiliary rupture of hepatic hydatid cyst: sonographic and cholangiographic appearances. GastrointestRadiol 1992;17: 41- 45.
- [12]. Kornaros SE, Aboul-Nour TA. Frank intrabiliary rupture of hydatid hepatic cyst: diagnosis and treatment. J Am CollSurg 1996;183: 466- 470.
- [13]. Ulualp KM, Aydemir I, Senturk H, et al. Management of intrabiliary rupture of hydatid cyst of the liver. World J Surg 1995;19: 720- 724.
- [14]. Magistrelli P, Masetti R, Coppola R, et al. Value of ERCP in the diagnosis and management of pre- and postoperative biliary complications in hydatid disease of the liver. GastrointestRadiol 1989; 14:315-320.
- [15]. Atli M, Kama NA, Yuksek YN, et al. Intrabiliary rupture of a hepatic hydatid cyst: associated clinical factors and proper management. Arch Surg 2001;136:1249-1255.
- [16]. vonSiner WN: Ultrasound, CT and MRI of ruptured and disseminated hydatid cysts. Eur J Radiol 1990, 11:31-37.
- [17]. Agarwal S, Sikora SS, Kumar A, et al. Bile leaks following surgery for hepatic hydatid disease. Indian J Gastroenterol 2005, 24:55-58.